



# What is Blepharitis?

Blepharitis is an inflammation of the eyelids. It is a chronic condition, but it can be ameliorated by self-care.

It is not sight threatening, but it is troublesome as it is chronic and the symptoms recur. In some patients it is associated with inflammation of the skin on the face (rosacea).

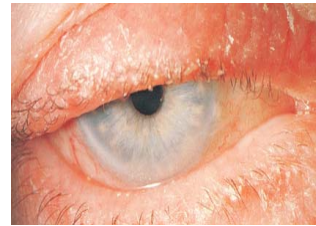
Blepharitis can affect the front part of the eyelids (anterior blepharitis/ seborrheic blepharitis) or the back portion of the eyelids (posterior blepharitis / meibomianitis) that are in contact with the front of the eye-ball.

With anterior blepharitis, the symptoms usually consist of irritation, dryness, crusting and discharge. With posterior blepharitis, the symptoms are similar, as well as the formation of recurrent eyelid cysts. The latter are due to blockage and inflammation of the glands on the eyelid which are arranged in a row behind the eyelashes. These meibomian glands produce an oily component of the tears and when the gland is blocked, the contents build up and a cyst may be formed. This can become inflamed (a sty) due to the body's natural healing response.

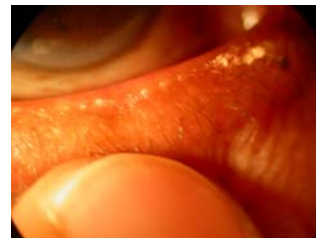The symptoms can be improved or relieved by performing some of the treatments listed below. These help to control the inflammation of the eyelids, but they are not a cure as the condition will remain, although it will be less problematic. It can take about three months to gain some control of the blepharitis, and then continuing treatment is required to prevent exacerbations.

## Treatment

- Hot compression  
With meibomianitis and/or meibomian cysts, holding a clean hand-towel soaked in comfortably hot water against the eyelid for several minutes can liquefy the contents of the meibomian glands or cysts and help release these. A commercially available product is available (eyebag).
- Lid hygiene  
Clean away any crusts on the eyelids and any secretions over the eyelid glands by using cotton wool buds dipped in baby shampoo. This is best performed last thing at night just before you sleep.



Anterior blepharitis with crusting and inflammation of the eyelid margins.



Posterior blepharitis with eyelid margin inflammation with excess secretions from the meibomian glands, as well as telangiectatic vessels and irregularity of the eyelid margin.

Standing in front of the mirror, dip a cotton wool bud into the baby shampoo, pull one of the lower lids down and wipe the shampoo along the eyelid just behind the eyelashes. Do this twice, once in each direction, then wet the other side of the cotton bud with water and wipe away the residual shampoo. Do this to the remaining three eyelids using a separate cotton bud for each eyelid. Do not dip a used cotton bud into the baby shampoo.

- **Eye lubrication**  
In some patients with blepharitis, the tears can break up very quickly as they are of poor quality, even though the eye may not be dry. Symptoms can be improved by instilling eye drops that stabilise the tears. These can be inserted as often as required. Ointment inserted to the eyes at bedtime can improve the comfort of the eyes on waking.
- **Other treatments**  
In severe cases of blepharitis, other treatments may be required, such as topical steroids, topical antibiotics or oral antibiotics.



Mr S A SADIQ DO MRCOphth FRCS FRCOphth DM  
CONSULTANT OPHTHALMIC SURGEON



### **Ahmed's career**

Ahmed qualified from the University of London in 1987, and started training in Ophthalmology in London in 1989. He was a registrar and a fellow in Nottingham, and was appointed as Consultant Ophthalmic Surgeon specialising in phacoemulsification and oculoplastics at the Manchester Royal Eye Hospital in December 1998. He has over 40 publications, more than 40 presentations, and a DM (thesis on endonasal laser DCR).

### **Ahmed's roles at the Manchester Royal Infirmary & University**

Ahmed interviews for the Medical School, and teaches medical and optometry students. He examines medical students, and for the MOptom. He is a member of the Local Negotiating Committee on behalf of the Manchester Royal Eye Hospital, and is a North West Representative of the Hospital Consultants and Specialists Association. He has raised money for the New Children's Hospital by arranging sponsored events. Ahmed has drafted a new mobile telephone use policy for the Trust which will become part of the hospital's policies.

### **Ahmed's roles outside CMMC**

Ahmed is a nominated representative of the Royal College of Ophthalmologists (RCOphth) on the General Optical Council (GOC). He is a Member of The RCOphth and a Founder Member of The British Oculoplastic Surgery Society. He is an examiner for the RCOphth as well as part of the Training The Trainers and Microsurgical Skills faculties. He has an interest in facial palsy management and is a medical adviser to the British Acoustic Neuroma association. He used to work as an Ophthalmic Medical Practitioner whilst a registrar, is a member of the Ophthalmic Qualifications Committee of the British Medical Association, and is involved with the Education Visitor Panel of the GOC.

He is active in research, a journal editor and reviewer. He is a committee member of the British International Doctors Association. He is a medical member of the Appeal Panel of The Postgraduate Medical Training and Education Board. As well as a journal reviewer, he is a reviewer for Research for Patient Benefit and Map of Medicine.

Outside medicine, Ahmed is a school governor, is involved with medical charities and community finance initiatives, and is co-chair of the Manchester Christian-Muslim Forum.

---

The Alexandra Hospital  
Mill Lane  
Cheadle  
Cheshire SK8 2PX

t +44 (0)161 495 7000/1/2/3  
f +44 (0)161 428 3666  
e a.sadiq@manchester.ac.uk  
w www.TheEyeSpecialist.co.uk